







Necrotizing complication and intercurrents in rhinomodeling with hyaluronic acid: integrative literature review

Complicações necrosantes e intercorrências na rinomodelação com ácido hialurônico: revisão integrativa da literatura



Maria Eduarda Beserra de Oliveira Menezes¹  Igor Tavares Hiluey Agra¹ 
Mélanie Fernandes do Carmo¹  Rennaly de Freitas Lima¹ 

¹ Centro Universitário UNIFACISA. Campina Grande, Paraíba, Brazil.

Abstract

Objective: To describe the adverse events, intercurrents, and complications of rhinomodeling with hyaluronic acid and indicate the possible causes for problems after the procedure. **Methods:** This integrative review was conducted in the Medline/PubMed, SciELO, and LILACS databases. The search included articles from 2013 to 2023 and used the following descriptors: hyaluronic acid, necrosis, dermal fillers, and nose. The integrative search combined the descriptors using the Boolean operator AND. Nine publications were analyzed. **Results:** The selected articles were identified, and data related to title, author, year of publication, type of study, methodology, main intercurrents, and conclusion were retrieved. Complications after the application of hyaluronic acid are not frequent. The first signs and symptoms must be analyzed to avoid complications, followed by applying the most appropriate protocol for prevention or reversal. **Conclusion:** The application of fillers following simple steps and knowledge about anatomy can be optimal options for safe and comprehensive rhinomodeling.

Keywords: Hyaluronic acid; Necrosis; Dermal fillers; Nose.

How to cite: Oliveira **MEBM**, Agra **ITH**, Carmo **MF**, Lima **RF**. Necrotizing complications and intercurrents in rhinomodeling with hyaluronic acid: integrative literature review
An Fac Med Olinda 2023; 1(10):58 <https://doi.org/10.56102/afmo.2023.313>

Corresponding Author:

Maria Eduarda Beserra de Oliveira Menezes
E-mail:
dra.eduardaoliveiram@gmail.com

Funding: Not applicable

Research Ethics

Committee (CAAE): Not applicable

Received: 02/08/2023

Approved: 20/09/2023

Resumo

Objetivo: Descrever os efeitos adversos, intercorrências e complicações do preenchimento com ácido hialurônico na região de nariz, indicando possíveis causas para os problemas apresentados após o procedimento. **Metodologia:** Trata-se de uma revisão integrativa realizada nas seguintes bases de dados: Medline via PubMed, SciELO e Lilacs, com artigos incluídos no período 2013 a 2023, utilizando os descritores, Ácido hialurônico; Necrose; Preenchedores dérmicos; Nariz. A busca integrada foi realizada unindo os descritores com o operador booleano “AND”. Foram analisadas 9 publicações. **Resultados:** Foi realizada a identificação dos trabalhos selecionados, elencando-se os dados relacionados à título, autor, ano de publicação, tipo de estudo, metodologia, principais intercorrências encontradas e a conclusão do estudo. Após análise dos estudos, observou-se que a ocorrência de complicações após a aplicação de ácido hialurônico não é frequente. Para que não ocorra o agravamento, é necessário que os primeiros sinais e sintomas sejam analisados para assim seguir com o protocolo mais adequado a fim de prevenir ou reverter. **Conclusão:** Seguindo passos simples de segurança e tendo um conhecimento anatômico refinado, os preenchedores podem ser uma boa ferramenta para um aprimoramento seguro e abrangente da rinomodelação.

Palavras-chave: Ácido hialurônico; Necrose; Preenchedores dérmicos; Nariz.

INTRODUCTION

Vanity is commonly associated with aesthetic procedures to improve appearance. Besides the nasal configuration having a fundamental role in balance, harmony, and facial proportion, each nasal structure has an exclusive aesthetic beauty. Also, the inclination of the nose in relation to the face contributes to an aesthetic aspect that refers to beauty.¹ In this context, non-surgical rhinoplasty (i.e., rhinomodeling) stands out among the main existing aesthetic procedures.

Rhinomodeling with hyaluronic acid (HA) is a simple and quick procedure that provides satisfactory results, similar to surgical rhinoplasty, and does not need absence from activities during recovery.² HA is considered the preferred product for rhinomodeling because it is moldable (e.g., enables skin remodeling in the nose region), has immediate and lasting results, and can be reversible after injecting hyaluronidase.³ HA is a biodegradable filler (i.e., non-permanent) absorbed by the body within 6 to 18 months. Refinements in application techniques and technological advances in injectable products based on HA are some factors that helped this product reach the gold standard as a filler agent.^{1,4} Complications after the application of HA in rhinomodeling are uncommon, and some adverse events are considered mild. However, severe adverse events, such as ischemia and necrosis, may also occur.⁵

The nasal region is located in the median plane of the face (middle third) and corresponds to a pyramidal protrusion called external nose. This structure is distinguished by its several small and fragile vessels, nerves, and a subcutaneous layer with limited adipose tissue.⁶ The two semi-rectangular and oblique nasal bones cover approximately one-third of the nasal dorsum.

The upper lateral nasal cartilage connects to the upper margin of the septal cartilage and can be separated by a small gap in the anterior-inferior part. Also, the greater alar cartilage, a flexible and thin plate present below the lateral nasal cartilage, forms a sharp curve in the anterior region of the nostrils that divides into two branches: medial and lateral.⁷

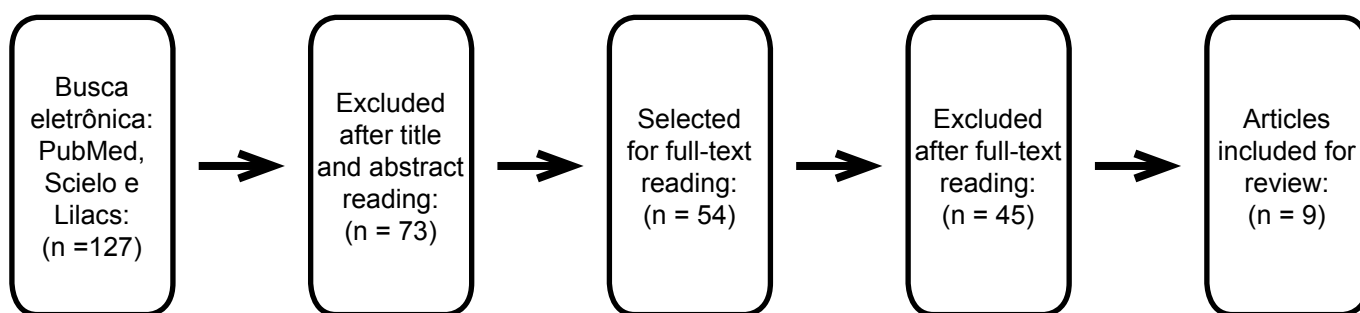
In this context, this study aimed to describe the necrotizing complications and interurrences in rhinomodeling with HA by analyzing the effects of this procedure and the possible causes for problems after filling.

METHODS

This study is an integrative review of literature on the effects, complications, and interurrences of rhinomodeling with HA in the nose region. This type of review allows a broad view of a topic that has the potential to gather diverse primary research methods to become a larger part of evidence-based practice initiatives.⁸

The search was conducted from December 2022 to May 2023 in the Medline/PubMed, SciELO, and LILACS databases using the following keywords: “hyaluronic acid”, “necrosis”, “dermal fillers”, and “nose”. The integrative search was performed by combining the descriptors using the Boolean operator AND.

Scientific articles covering the proposed topic in the title, abstract, or descriptors and published in English or Portuguese between 2013 and 2023 were included. Those articles not related to the topic and unavailable in full were excluded. Editorials, letters to the editor, opinion articles, duplicate articles, dissertations, and theses were also excluded. The articles found and published until May 2023 were selected for title and abstract reading. After this phase, the selected articles were read in full.



Source: Authors

Figure 1. Flowchart of study selection

RESULTS

Nine studies published between 2013 and 2020 in national and international journals were selected. Table 1 presents the characteristics of the articles according to author, year of publication, objectives, main complications and interurrences, and conclusions of the study.

Two studies were retrospective reviews from 2015 and 2019, two were cross-sectional studies published in 2019, and five were case reports published between 2013 and 2020.

Complications after rhinomodeling are uncommon and may range from hematomas, edema, and delayed granulomatous reactions to more severe skin necrosis.

Table 1. Characterization of the included studies

Authors	Objectives	Intercurrences and complications	Conclusions of the studies
Lee J. <i>et al.</i> , 2017. ⁹	Describe a case of blepharoptosis and skin necrosis resulting from rhinoplasty.	Ecchymosis on the left nasal ridge, ptosis of the left eye, conjunctival hyperemia, and dilated pupil in the left eye were observed.	The skin lesion was treated twice daily with epidermal growth factor spray and antibacterial ointment. The skin lesion improved after six months, and the persistent diplopia was progressively resolved.
Kwon SG. <i>et al.</i> , 2013. ¹⁰	Report a case of ischemic oculomotor nerve palsy and skin necrosis after filler injection.	Blepharoptosis, exotropia, and diplopia developed suddenly after injection, followed by gradual skin necrosis.	The symptoms and signs of oculomotor nerve palsy improved with steroid therapy. Consultations and cooperation with ophthalmologists are needed.
Oh BL. <i>et al.</i> , 2014. ¹¹	Report a case of intra-arterial infusion of hyaluronidase into the ophthalmic artery and other arteries supplying the facial skin.	The increased tissue pressure probably allowed filler particles to pass through the anastomosis and reach the artery.	Although intra-arterial infusion of hyaluronidase failed to recanalize the central retinal artery and improve vision, the authors achieved partial recanalization of the ophthalmic artery and its branches and restored ocular motility.
Rivkin A. 2019. ¹²	Determine the overall adverse events rate for non-surgical rhinoplasty.	The overall adverse events rate was 7.6%; five cases (0.20%) were considered severe (ischemia and necrosis).	Rhinomodeling is a relatively safe procedure, and most reactions are present in common sites of adverse events. Patients with previous surgical rhinoplasty demonstrated a significantly higher chance of adverse events.

Harb A, Brewster CT. 2019. ¹³	Review the demographics, indications, treatments, and results of treated patients.	Swelling and erythema were self-limited adverse event in approximately half of patients. Infection and localized skin necrosis were observed in two and three patients, respectively.	Non-surgical rhinoplasty is a safe procedure with positive aesthetic results when performed by an experienced clinician.
Furtado, GRD <i>et al.</i> , 2020. ¹⁴	Report a case of treatment of complications after aesthetic rhinomodeling.	The patient (no history of systemic diseases) underwent rhinomodeling. After 24 hours, the patient reported edema, purplish color, and paleness at the nose tip. Subsequently, an injection of hyaluronidase (1000U) was applied.	The areas affected after rhinomodeling (nose tip, columella, and upper lip) progressed to necrosis. After adequate treatment, a small scar remained compared to the initial lesions.
Sun, ZS <i>et al.</i> , 2015. ¹⁵	Report a study with 20 patients that developed necrosis after hyaluronic acid fillers.	Twenty patients developed impending nasal skin necrosis as a primary concern after nose or nasolabial fold augmentation with fillers or both.	Filling the nose and nasolabial folds with hyaluronic acid fillers may lead to nasal skin necrosis, possibly due to intravascular embolism or extravascular compression or both. Early combination treatment (<2 days) with hyaluronidase is associated with complete resolution of the complication.
Ramos, R <i>et al.</i> , 2019. ¹⁶	Describe a technique for applying fillers to the nose, paying attention to safety aspects.	Nasal tip edema, pain, and satisfaction with the result were evaluated. A total of 52% of patients had mild edema, 74% had mild pain, 15% were very satisfied, and 74% were satisfied with the results.	Rhinomodeling with resorbable fillers is a simple procedure with acceptable aesthetic results. However, in-depth anatomical knowledge is needed to reduce the risks of complications.
Chen, Q <i>et al.</i> , 2016. ¹⁷	To present a typical case of skin necrosis after non-surgical rhinoplasty with hyaluronic acid.	The patient felt intense pain, and the skin on the intermediate forehead turned pale. Persistent sensitivity was reported, and a progressive change in skin color was noted before returning to the hospital 48 hours later.	Surgeons and dermatologists must know the vascular anatomy before performing hyaluronic acid injections.

DISCUSSION

According to the analyzed studies, several complications related to HA have been described. However, each author presented methods and measures based on clinical experience,

indicating a lack of consensus regarding the appropriate technique and consideration about severe complications.

Harb and Brewster¹³ emphasized that rhinomodeling was a safe procedure with positive aesthetic results when performed by an experienced clinician. However, swelling and erythema might occur due to allergic reactions in people sensitive to the filler. Comprehensive training and the use of appropriate materials are needed, considering that the first strategy against vascular complications is prevention. Ramos *et al*¹⁶ reported that risk factors (e.g., bruising and swelling) are common in the short term; thus, in-depth knowledge of nasal anatomy is also needed to avoid applications in regions of higher risk.

Sun *et al*¹⁵ reported a study of 20 consecutive patients who developed impending nasal skin necrosis as a primary concern after nose or nasolabial fold augmentation with HA fillers or both. Seven patients developed total skin necrosis, and thirteen patients fully recovered after a combination treatment with hyaluronidase. Also, 85% of those who developed total skin necrosis were late presenters and did not receive the combination treatment with hyaluronidase within two days after the vascular complication. Ischemia needs to be early identified and treated to prevent its progress to necrosis. The early combination treatment (before two days) with hyaluronidase was associated with complete resolution of the complication.

Hyaluronidase is an enzyme that accelerates the absorption of the filler by the body. In the study by Furtado *et al*¹⁴, hyaluronidase was used in the reversal process. The patient was 34 years old, female, without history of systemic diseases, and underwent rhinomodeling with 0.8 mL of hyaluronic acid between the nasal dorsum, nasal spine, and columella. Edema, purplish color, and pallor on the nose tip were reported after 24 hours of the procedure; the patient used a cold compress in the region until the next day. The patient reported burning in the mouth on the third day and underwent an injection of 1000IU of hyaluronidase, warm compresses several times a day, and oral medication (acetylsalicylic acid 500 mg every 12 hours for 7 days). Subsequently, skin damage and persistence of redness were observed. The patient improved progressively after 30 sessions of hyperbaric oxygen therapy and medication. Despite the positive evolution, cold compresses are not recommended for treating necrosis because of the vasoconstriction and potential decrease in blood supply.

Chen *et al*¹⁷ reported a case who experienced severe pain and pale skin on the mid-forehead during non-surgical rhinoplasty. The patient subsequently developed persistent sensitivity and progressive changes in skin color, resulting in hospitalization and surgical decompression of the nasal tip. Vasodilator, antimicrobial, and supportive treatment, including hyperbaric oxygen therapy, were used. Despite treatments, the affected area showed notable roughness and angulation in the bilateral soft triangles.

The interurrences and complications of rhinomodeling are not limited to the nose region.

A case of a healthy female patient, 20 years old, who underwent filling of the nasal dorsum with HA developed partial visual impairment, pain on the right side of the eye, nausea, vomiting, and headache¹⁰.

Oh et al¹¹ also reported a case of visual loss following the application of HA. A 33-year-old female patient arrived in the emergency room with sudden visual loss in the right eye. Ten hours earlier, the patient had undergone HA injection in the glabella and nasal ala. Retinal arterial perfusion was not restored despite direct infusion of hyaluronidase into the ophthalmic artery; however, branches of the ophthalmic and facial arteries were recanalized. Skin discoloration was normalized, while retinal perfusion and eye movement were partially and fully recovered, respectively.

All studies confirmed the importance of early diagnosis since, when treated correctly, it may guarantee the safety and success of results. Lee *et al*⁹ reported a case of a 25-year-old female patient admitted to the plastic surgery service of the hospital due to severe pain, blepharoptosis, and decreased visual acuity immediately after filler injection. The patient received a hyaluronidase injection immediately after the interurrence. Almeida and Saliba¹⁸ suggested that, although hyaluronidase influenced the reduction of vascular complications caused by the filler, its isolated use might be ineffective if applied more than 24 hours after the filler injection.

Last, Rivkin¹² contributed to literature regarding rhinomodeling with injectable fillers by performing a retrospective chart review of 2,488 procedures. The overall rate of adverse events was 7.6%, and previous surgical rhinoplasty increased by 51% the chances of adverse events. Injecting fillers into the nasal tip or lateral wall significantly increased the chances of adverse events compared with other areas, regardless of prior surgery status. The author also reinforced the caution when injecting the nose, regardless of surgical history, and the need for experienced professionals with in-depth knowledge of nasal anatomy.

CONCLUSION

Rhinomodeling with HA presents significant risks, including infection, allergic reactions, aesthetic irregularities, necrosis, hematoma, material displacement, and abnormal healing. Comprehensive assessments by experienced professionals and an open discussion about the medical history are essential to minimize the risks and ensure safe and satisfactory results. The reaction of the body after the procedure must also be observed since immediate adverse events may occur. The management of complications includes hyaluronidase to remove HA and antibiotics to prevent infections. In conclusion, rhinomodeling is safe when performed by trained and experienced professionals with knowledge of nasal anatomy and appropriate techniques (e.g., cannulas, small boluses, and prior aspiration). Applying fillers and prophylactic measures are optimal options for a safe rhinomodeling procedure.

CONFLICTS OF INTEREST

The authors declare no conflicts of interest.

AUTHOR CONTRIBUTIONS

MEBOM: conceptualization, data analysis, supervision, validation, visualization, writing of the original draft, and revision and editing. **ITHA:** data analysis, validation, visualization, and writing of the original draft. **MFC:** data analysis, validation, visualization, and writing of the first draft. **RFL:** conceptualization, data analysis, methodology, project administration, supervision, validation, visualization, writing of the original draft, and review and editing. All authors approved the final version.

REFERENCES

1. Furtado R. Morfologia nasal: harmonia e proporção aplicadas à rinoplastia. *Rev Bras Cir Plast.* 2016;3(4). doi.org/10.5935/2177-1235.2016RBCP0100
2. Frisina AC, Barbosa BO, Texeira GH, Fernandes RL. Rinomodelação com ácido hialurônico: técnicas, riscos e benefícios. *Rev. Bras. Cir. Plást.* 2021;36(1):108-114. doi.org/10.5935/2177-1235.2021RB-CP0020
3. Almeida A, Sampaio G. Ácido hialurônico no rejuvenescimento do terço superior da face: revisão e atualização - Parte 1. *Surg. Cosm. Dermat.* 2015; 8(2). doi: http://dx.doi.org/10.5935/scd1984-8773.20168203
4. Nikolis, A, Enright, KM, Berros, P, Sampalis, JS. Safety of infraorbital hyaluronic acid injections: Outcomes of a meta-analysis on prospective clinical trials. *J Cosmet Dermatol.* 2023; 22: 2382-2390. doi:10.1111/jocd.15925
5. Souza B, Felix Bravo B, Klotz De Almeida Balassiano L, Roos Mariano Da Rocha C, Barbosa De Sousa Padilha C, Martinez Torrado C, *et al.* Delayed-type Necrosis after Soft-tissue Augmentation with Hyaluronic Acid. *J Clin Aesthet Dermatol.* 2015 Dec;8(12):42-7. PMID: 26705447; PMCID: PMC4689510.
6. Altruda L. *Anatomia Topográfica Da Cabeça E Do Pescoço.* Edit Manole Ltda. 2005; 1- 128
7. Silveira A, Marcuzzo M, Girardello K. As implicações do preenchimento com ácido hialurônico para o aperfeiçoamento estético do nariz e as possíveis intervenções clínicas biomédicas no tratamento das intercorrências. *Rev Extensão Iniciação Cient UNISOCIESC.*2021;8(2). https://reis.unisociesc.com.br/index.php/reis/article/view/281
8. Whittemore R, Knafl K. The integrative review: updated methodology *J. Adv. Nurs.*, 52 (5) (2005), pp. 546-553, doi: 10.1111/j.1365-2648.2005.03621.x.
9. Lee JI, Kang SJ, Sun H. Skin Necrosis with Oculomotor Nerve Palsy Due to a Hyaluronic Acid Filler Injection. *Arch Plast Surg.* 2017 Jul;44(4):340-343. doi: 10.5999/aps.2017.44.4.340

10. Kwon SG, Hong JW, Roh TS, Kim YS, Rah DK, Kim SS. Ischemic oculomotor nerve palsy and skin necrosis caused by vascular embolization after hyaluronic acid filler injection: a case report. *Ann Plast Surg*. 2013 Oct;71(4):333-334. doi: 10.1097/SAP.0b013e31824f21da
11. Oh BL, Jung C, Park KH, Hong YJ, Woo SJ. Therapeutic Intra-arterial Hyaluronidase Infusion for Ophthalmic Artery Occlusion Following Cosmetic Facial Filler (Hyaluronic Acid) Injection. *Neuroophthalmology*. 2014 Jan 28;38(1):39-43. doi: 10.3109/01658107.2013.830134
12. Rivkin A. Rinoplastia não cirurgica com preenchimentos injetáveis: Uma revisão de segurança dos procedimentos. *Cirurg Plást Med Est*. 2019. doi: 10.5935/2177-1235.2021RBCP0020
13. Harb A, Brewster CT. The Nonsurgical Rhinoplasty: A Retrospective Review of 5000 Treatments. *Plast Reconstr Surg*. 2020 Mar;145(3):661-667 doi: 10.1097/PRS.0000000000006554
14. Furtado GRD, Barbosa KL, Tardini CD, Barbosa JR, Barbosa CM. Necrose em ponta nasal e lábio superior após a rinomodelação com ácido hialurônico - relato de caso. *Aesth Orofacial Sci*. 2020;01(01):62-67. doi: <https://doi.org/10.51670/ahof.v1i1.17>
15. Sun ZS, Zhu GZ, Wang HB, Xu X, Cai B, Zeng L, *et al*. Clinical Outcomes of Impending Nasal Skin Necrosis Related to Nose and Nasolabial Fold Augmentation with Hyaluronic Acid Fillers. *Plast Reconstr Surg*. 2015 Oct;136(4):434 -441. doi: 10.1097/PRS.0000000000001579
16. Ramos RM, Bolivar HE, Piccinini PS, Sucupira E. Rinomodelação ou rinoplastia não-cirúrgica: uma abordagem segura e reprodutível. *Rev. Bras. Cir. Plást*. 2019;34(4):576-581 doi: doi.org/10.5935/2177-1235.2019RBCP0242
17. Chen Q, Liu Y, Fan D. Serious Vascular Complications after Nonsurgical Rhinoplasty: A Case Report. *Plast Reconstr Surg Glob Open*. 2016 Apr 21;4(4): 683. doi: 10.1097/GOX.0000000000000668
18. Almeida ART, Saliba AFN. Hialuronidase na cosmiatria: O que devemos saber? *Surg Cosmet Derma*. 2015;7(3). doi: <https://doi.org/10.5935/scd1984-8773.20157>