










# Angioarchitecture of the middle meningeal artery in human skulls: a morphometric study

## Angioarquitetura da artéria meníngea média em cabeças ósseas humanas: um estudo morfométrico



Ismael Felipe Gonçalves Galvão<sup>1</sup>  Fernando Augusto Pacífico<sup>1</sup>   
Bruna Laryssa Santos Borges Machado<sup>1</sup>  Isabella Cristina Oliveira Pacheco<sup>1</sup>   
Luciana Larissa Rodrigues dos Santos Queiroz<sup>1</sup>  Renata Cristinny de Farias Campina<sup>2</sup>   
Olávio Campos Júnior<sup>1</sup> 

<sup>1</sup> Faculdade de Medicina de Olinda. Olinda, Pernambuco, Brazil.

<sup>2</sup> Universidade Federal de Pernambuco. Recife, Pernambuco, Brazil.

### Abstract

**Introduction:** The middle meningeal artery (MMA) is clinically and surgically relevant, and knowledge regarding its angioarchitecture is essential in various procedures. However, literature lacks studies exploring its morphometric aspects. **Objectives:** This study aimed to analyze the MMA sulci morphometry using a digital approach. **Method:** Thirty-five skulls with a complete visualization of the MMA sulcus were selected. From this, the length of the main trunk and parietal and frontal branches, the inter-branch angle, and the diameter of the foramen spinosum were measured bilaterally using the ImageJ<sup>®</sup> software. **Results:** Morphometric data showed no differences in the morphometry of the main trunk and parietal branch according to laterality. On the other hand, the length of the frontal branch was higher on the right side of the skulls. No differences were observed in the measurements of the foramen spinosum and the inter-branch angle. **Conclusion:** Digital methods for morphometric analysis of the MMA offer advantages in terms of precision and speed in obtaining data. Also, the MMA exhibits few bilateral morphometric variations that should be considered for planning surgical procedures and as a basis for future analyses.

**Keywords:** Anatomy, Cerebral arteries, Clinical relevance.

**How to cite:** Galvão IFG, Pacífico FA, Machado BLSB, Pacheco ICO, Queiroz LLRS, Campina RCF et al. Angioarchitecture of the middle meningeal artery in human skulls: a morphometric study. *An Fac Med Olinda* 2024; 1(11):42 doi: <https://doi.org/10.56102/afmo.2024.311>

#### Corresponding author:

Fernando Augusto Pacífico.  
E-mail: [fapacifico@outlook.com](mailto:fapacifico@outlook.com)

**Funding:** None

**Ethics approval:** n° 5.689.062

Received: 07/06/2023

Approved: 02/07/2024

## Resumo

**Introdução:** A artéria meníngea média (AMM) possui grande relevância clínica e cirúrgica, e o conhecimento da sua angioarquitetura é importante em vários procedimentos, no entanto, é evidente a escassez de estudos sobre seus aspectos morfométricos. **Objetivos:** O presente estudo objetivou analisar a morfometria dos sulcos da AMM por meio de uma abordagem digital. **Método:** Foram selecionadas 35 cabeças ósseas por permitirem a visualização completa do sulco da AMM, das quais foram medidos os comprimentos do tronco principal, dos ramos parietal e frontal, o ângulo inter-ramos e o diâmetro do forame espinhoso bilateralmente com o auxílio do *software* ImageJ®. **Resultados:** Os dados morfométricos foram facilmente obtidos e não foram observadas diferenças na morfometria bilateral do tronco principal e do ramo parietal, no entanto, o comprimento do ramo frontal foi maior no antímero direito. Também não foram encontradas diferenças nas medidas do forame espinhoso e do ângulo inter-ramos. **Conclusão:** Métodos digitais de análise morfométrica da AMM são vantajosos em termos de precisão e rapidez na obtenção de dados. Por outro lado, a AMM apresenta poucas variações morfométricas bilateralmente, representando importantes achados que devem ser observados cuidadosamente no planejamento de procedimentos cirúrgicos e servir de base para futuras análises.

**Palavras-chave:** Anatomia; Artérias cerebrais; Relevância clínica.

## INTRODUCTION

The middle meningeal artery (MMA) is the main human dural artery. Its origin and course may vary according to the embryological development of the stapedia system, internal carotid artery, ophthalmic artery, trigeminal artery, and inferolateral trunk<sup>1</sup>. In most cases, the MMA originates from the internal maxillary artery, enters the middle cranial fossa through the foramen spinosum, laterally crosses the bone crest, and curves anteriorly above the greater sphenoid wing<sup>2</sup>.

The embryological origin and intimate relationship of the MMA with the cranial vault confer clinical and surgical relevance<sup>3</sup>. Studies regarding the morphological aspects reported its complex development from the stapedia system, present in embryonic development, as the origin of a large number of anatomical variations<sup>1,4</sup>.

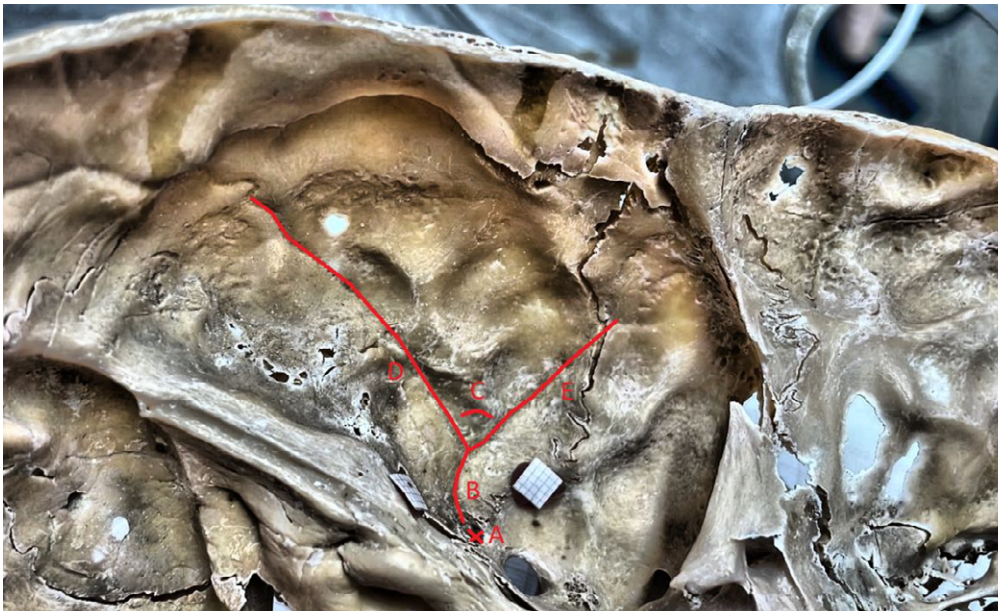
The MMA is vulnerable to head trauma and may lead to pseudoaneurysms and bleeding due to the unique anatomical characteristics and proximity to the temporal bone. In addition, this artery is likely involved in mechanisms regarding chronic headaches associated with arterial vasodilation or neurogenic inflammation<sup>5</sup>. Knowledge of the MMA angioarchitecture is also important in several procedures, such as devascularization of dura mater tumors and epidural hematomas, and in understanding clinical conditions (e.g., migraine)<sup>4,6</sup>. In this context, a morphometric analysis may provide unique information regarding the size, location, and geometric characteristics of MMA that may help elucidate surgical and radiological approaches<sup>7,8</sup>.

Despite studies addressing the morphological and embryological aspects of the MMA,

literature still lacks information regarding its morphometry<sup>4,6</sup>. Therefore, the present study aimed to provide new findings about the MMA by investigating its angioarchitecture in human cadaveric skulls using an innovative approach. We presented a morphometric analysis as a function of laterality and the possible relationships of these aspects with clinical-surgical implications.

## METHOD

This cross-sectional study evaluated 100 human skulls from the anatomical collection of the Department of Anatomy at a higher education institution. The 35 selected heads were analyzed using millimeter scales to standardize measurements and calibrate the software. Then, the images were obtained using a Finepix S4800 digital camera (Fujifilm Corp., Tokyo, Japan) and transferred to a microcomputer for analysis using the ImageJ® software (version 1.46r 2012). From this, calculations determined the length of the main trunk, frontal branch, and parietal branch, the angle between the frontal and parietal branches (inter-branches), and the diameter of the foramen spinosum (Figure 1).



**Figure 1.** Internal view of the skull base showing the five measurements taken bilaterally: (A) diameter of the spinous foramen, (B) length of the main trunk, (C) angle between the frontal and parietal branches (inter-branches), (D) length of the parietal branch, and (E) length of the frontal branch.

Statistical analysis was performed using the SPSS® software (IBM Corp, Chicago, USA). Normality was verified using the Kolmogorov-Smirnov test, while data were compared using the Wilcoxon test. Measures of central tendency (mean, minimum, and maximum) and dispersion (standard deviation) were used to present non-normal data. All tests used  $p < 0.05$  as significance level.

## RESULTS

The present study used a pioneering digital approach to evaluate the MMA sulcus of 100 skulls. The morphometric evaluation was performed in the right (RA) and left (LA) antimeres of 35 skulls, as presented in Table 1. The remaining samples were considered losses due to damages or the inability to visualize the artery sulci bilaterally.

**Table 1.** Morphometric data of the middle meningeal artery in humans measured on the right and left antimeres.

Variables	RA	LA	p-value
Main trunk (mm)	14.58 ± 9.52 (3.1 - 53.5)	16.01 ± 12.18 (4,9 - 59,3)	0.87
Parietal branch (mm)	28.98 ± 17.89 (8.3 - 80.4)	30.38 ± 17.24 (11.8 - 67.7)	0.74
Frontal branch (mm)	26.83 ± 16.67 (9.60 - 87.40)	29.89 ± 12.77 (10.5 - 68.7)	0.01**
Inter-branch angle (°)	89.66 ± 16.83 (91.0 - 122.0)	85.91 ± 24.64 (22.0 - 126.0)	0.70
Foramen spinosum (mm)	2.14 ± 0.40 (1.50 - 3.10)	2.15 ± 0.44 (1.10 - 3.0)	0.77

Values represent mean ± standard deviations; median (minimum-maximum).  
Wilcoxon test:  $p \leq 0.05$  (\*),  $p \leq 0.01$  (\*\*); RA: Right antimeres; LA: Left antimeres.

No differences were observed in the length of the main trunk (RA: 14.58 ± 9.52 mm and LA: 16.01 ± 12.18 mm,  $p = 0.870$ ) and parietal branch (RA: 28.98 ± 17.89 mm and LA: 30.38 ± 17.24 mm,  $p = 0.743$ ). However, the length of the left frontal branch was significantly greater than the right frontal branch (29.89 ± 12.77 mm and 26.83 ± 16.67 mm, respectively,  $p = 0.011$ ). Last, no differences were found in the diameter of the foramen spinosum (RA: 2.14 ± 0.40 mm and LA: 2.15 ± 0.44 mm,  $p = 0.771$ ) and the angle between the frontal and parietal branches (RA: 89.66 ± 16.83° and LA: 85.91 ± 24.64°,  $p = 0.700$ ).

## DISCUSSION

Aragón-Sánchez et al.<sup>9</sup> discussed the use of the ImageJ<sup>®</sup> software as a morphometric study tool, highlighted its efficiency and ease of use for measuring structures, and demonstrated excellent reliability by using an inter-rater model and 95% confidence intervals.

From this perspective, Tobin et al.<sup>10</sup> studied the implementation of a new automated morphometric analysis to study peripheral nerves based on the ImageJ<sup>®</sup> software. They did not observe a statistically significant difference ( $p > 0.05$ ) between manual measurements and the new method using the software and concluded that the new approach had advantages, such as great-

er convenience, time efficiency, precision, and lower operator error or bias<sup>10</sup>. In our study, this tool promoted an efficient and reliable measurement of structures consistent with literature<sup>9,10</sup>.

The MMA sulcus was present bilaterally in all skulls evaluated, consistent with conventional descriptions in textbooks<sup>11</sup>. Using an innovative approach, the observations in this study revealed that the MMA did not present variations in the length of the main trunk, parietal branch, and diameter of the foramen spinosum or inter-branch angle between sides.

Few studies addressed the morphometric aspects of the MMA and the correlations between its vascular anatomy and intrinsic and anthropometric factors of the individuals<sup>12</sup>. The middle fossa and its variations may offer a suitable surgical route to deal with injuries at the anterior and posterior cranial fossae junction. Thus, understanding anatomical landmarks and their variations is fundamental for effectively managing these injuries and avoiding disabling complications<sup>13</sup>. Also, this information is essential to predict the arterial involvement in fractures on the affected side of the skull.

The length of the main trunk of the MMA did not vary according to laterality, corroborating with previous studies<sup>4,6</sup>. On the other hand, Silva et al.<sup>6</sup> and Honnegowda et al.<sup>4</sup> observed bilateral variations in the length of the parietal branch, which were not observed in the present study, possibly due to differences in the sample, population, or method used between studies. Furthermore, we identified a bilateral difference in the length of the frontal branch, supporting the findings observed by Silva et al.<sup>6</sup>. Although other factors may also be involved, the complex embryological origin is the central thesis explaining these anatomical variations<sup>14</sup>.

The MMA is phylogenetically the most recent intracranial artery, with evolution and development closely related to the development of the cerebral lobes<sup>15</sup>. Its emergence is also closely related to the stapedia system, which is present in the first weeks of fetal development and degenerates around the tenth week<sup>1,16</sup>. Therefore, this artery is susceptible to anatomical variations and anastomoses and has great relevance for pathologies<sup>1, 17</sup>.

Some differences found in cranial irrigation may elucidate the variations in the frontal branch identified in the present study. According to Eisová et al.<sup>18</sup>, the macroscopic patterns of meningeal vessels with brachycephalic and mesocephalic neurocranial proportions are not influenced bilaterally by the sex or shape of the skull in modern European adult populations. However, the MMA is more dominant in the anterior endocranial regions<sup>18</sup>, which suggests greater angiogenic activities and may lead to variations in the length of the frontal branch. More studies are needed to clarify these characteristics.

Although a pioneering study suggested that MMA was more developed in the right antimer, the authors did not provide a quantitative assessment to support these conclusions<sup>19</sup>. Asymmetries in the path of these vessels are subtle and may be associated with cerebral asymmetries,

causing different distributions in intracranial pressure<sup>18</sup>. Nevertheless, the study reported a lack of experimental research supporting or contradicting this hypothesis<sup>19</sup>.

This study did not observe morphometric differences in the diameter of the spinosum foramen according to the laterality. This foramen is an important anatomical landmark for cranial fossa surgeries due to its neurovascular structures and may present significant differences according to laterality<sup>14, 20</sup>. Bioria e Silva et al.<sup>12</sup> observed a mean foramen diameter between 1.8 and 2.8 mm, according to the laterality and sex of the individual, similar to the value found in the present study (2.0 mm).

The evaluation of the angle formed by the frontal and parietal branches of the MMA did not present morphometric differences bilaterally, corroborating the observations of previous studies<sup>4,6,20</sup>. In these cases, blood flow is inversely proportional to the angle formed by the vessels, increasing the possibility of dilation of the arterial wall and, consequently, the risk of aneurysm formation<sup>21</sup>. Despite this clinical importance, literature lacks morphometric studies regarding the angle formed by the MMA branches.

From this perspective, Ye et al.<sup>21</sup> observed positive relationships between vessel angles and the formation and rupture of aneurysms. The vessel angles may also be a predictive factor for these conditions. Another example is the reduction in the angle formed by the MMA and internal maxillary artery, which may increase the complexity of endovascular procedures and hamper the use of the guidewire and catheter<sup>22</sup>. Therefore, studying the angles formed by cerebral vessels is relevant for pathologies and during procedures, such as embolization<sup>21,22</sup>.

Last, the bilateral morphometric study of the MMA sulci in 35 skulls represents a great innovation and contribution. In this sense, more studies with larger sample sizes are needed to expand the knowledge about the MMA morphometric characteristics, confirm findings, and improve the understanding of variations in the development of the MMA branches in healthy adults.

## CONCLUSION

The values obtained in the measurements were efficient. Also, imaging processing using software was essential for studying cranial osteology and establishing specific morphometric patterns of the MMA. The main trunk, the parietal branch, the diameter of the foramen spinosum, and the inter-branch angle of the MMA did not vary bilaterally. However, the frontal branch exhibited variations in length according to antimerism. Last, neurosurgeons must be aware of this variation during surgical procedures in the middle cranial fossa.

## CONFLICTS OF INTEREST

Nothing to declare

## AUTHOR CONTRIBUTIONS

**IFGG:** Conceptualization, data curation, data analysis, research, methodology, development, software implementation and testing, data validation and experiments, writing original manuscript, review, and editing. **FAP:** Conceptualization, data curation, data analysis, research, methodology, project administration, supervision, validation of data and experiments, data presentation design and writing original manuscript, review, and editing. **BLSBM:** Search. **ICOP:** Search. **LLRSQ:** Search. **RCFC:** Supervision, methodology, provision of tools. **OCJ:** conceptualization, data curation, research, methodology, project administration, software implementation and testing, supervision, validation of data and experiments, data presentation design, review, and editing.

## REFERENCES

1. Bonasia S, Smajda S, Ciccio G, Robert T. Middle meningeal artery: Anatomy and variations. Vol. 41, *Am J Neuroradiol.*; 2020. p. 1777–85. doi: <https://doi.org/10.3174/ajnr.A6739>
2. Fantoni M, Eliezer M, Serrano F, et al. High frequency of ophthalmic origin of the middle meningeal artery in chronic subdural hematoma. *Neuroradiology.* 2020 May 1;62(5):639–44. doi: <https://doi.org/10.1007/s00234-020-02363-6>
3. Navarro-Orozco D, Sánchez-Manso JC. Neuroanatomy, Middle Cerebral Artery. 2023 Jul 24. In: StatPearls [Internet]. Treasure Island (FL): StatPearls Publishing; 2023 Jan–. PMID: 30252258.
4. Honnegowda TM, Dineshan V, Kumar A. Morphometry of organization of middle meningeal artery through the analysis of bony canal in human's skull: A clinico-anatomical and embryological insight. *J Craniovertebr Junction Spine.* 2019 Apr-Jun;10(2):127-130. doi: [https://doi.org/10.4103/jcvjs.JCVJS\\_45\\_19](https://doi.org/10.4103/jcvjs.JCVJS_45_19).
5. Sant'Anna MAF, Luciano LL, Chaves PHS, et al. Anatomy of the Middle Meningeal Artery. *Arq Bras Neurocir: Brazilian Neurosurgery.* 2021 Dec 3;40(04):e339–48. doi: <https://doi.org/10.1055/s-0041-1733863>
6. da Silva TH, Ellwanger JH, da Rosa Silva HT, et al. Morphometric Analysis of the Middle Meningeal Artery Organization in Humans—Embryological Considerations. *J Neurol Surg B Skull Base.* 2013 Jan 22;74(02):108–12. doi: <https://doi.org/10.1055/s-0033-1333615>
7. Gijzen FJH, Vis B, Barrett HE, et al. Morphometric and Mechanical Analyses of Calcifications and Fibrous Plaque Tissue in Carotid Arteries for Plaque Rupture Risk Assessment. *IEEE Trans Biomed Eng.* 2021 Apr;68(4):1429–38. doi: <https://doi.org/10.1109/TBME.2020.3038038>
8. Yagoub SME, Taib AA, Mansouri MY, Elfakhri A, Abdalla MA. Anatomical Variations, Parameters, and Morphometric Evaluation of Renal Arteries by Using Computerized Tomography Angiography. *Int. J. Clin. Ski.* 2022 Oct 29;16(10):265. DOI:10.37532/1753-0431.2022.16(1

- 0).265
9. Aragón-Sánchez J, Quintana-Marrero Y, Aragón-Hernández C, Hernández-Herero MJ. ImageJ: A Free, Easy, and Reliable Method to Measure Leg Ulcers Using Digital Pictures. *Int J Low Extrem Wounds* 2017;16(4):269-273. doi: <https://doi.org/10.1177/1534734617744951>
  10. Tobin CA, Wang Z, Zhang LL, et al. A new computerized morphometric analysis for peripheral nerve study. *J Reconstr Microsurg*. 2014;30(2):75-82. doi: <https://doi.org/10.1055/s-0033-1354738>
  11. Standring S, Ellis H, Healy JC, Johnson D. *Gray's anatomy*. 39th ed. London: Elsevier Churchill Livingstone; 2005. p. 442p.
  12. Boloria E Silva Y, Hirota VB, Augusto V, et al. Contribuição ao estudo morfológico dos sulcos da artéria meníngea média em crânios humanos cadavéricos. *RMS*. 2023;5(1):20–31.
  13. Maina R, Ducati A, Lanzino G. The middle cranial fossa: Morphometric study and surgical considerations. *Skull Base*. 2007 Nov;17(6):395–404. doi: <https://doi.org/10.1055/s-2007-991117>
  14. Galvão IFG, Pacífico FA. Angioarquitetura da artéria meníngea média. *Anais da Faculdade de Medicina de Olinda*. 2022 Dec 22;1(7):34–41. doi: <https://doi.org/10.56102/afmo.2022.178>
  15. Pallavi., Priyanka R, Sinha BK. A Morphometric Assessment of the Anatomical Variations in Branching Pattern of Middle Cerebral Artery: An Observational Study. *International Journal of Toxicological and Pharmacological Research [Internet]*. 2022;12(6):138–42.
  16. Natali AL, Reddy V, Leo JT. Neuroanatomy, Middle Meningeal Arteries. In: *StatPearls*. Treasure Island (FL): StatPearls Publishing; October 24, 2022. PMID: 30137830
  17. Kumar S, Mishra NK. Middle meningeal artery arising from the basilar artery: report of a case and its probable embryological mechanism. *J Neurointerv Surg*. 2012;4(1):43-44. doi: <https://doi.org/10.1136/jnis.2010.004465>
  18. Eisová S, Pířová H, Velemínský P, Bruner E. Normal craniovascular variation in two modern European adult populations. *J Anat*. 2019;235(4):765-782. doi: <https://doi.org/10.1111/joa.13019>
  19. Saban R. Image of the human fossil brain: endocranial casts and meningeal vessels in young and adult subjects . In: Jean-Pierre Changeux, Jean Chavillon, editors. *Origins of the human brain*. Oxford: Clarendon Press.; 1995. p. 11–38. doi: <https://doi.org/10.1093/acprof:oso/9780198523901.001.0001>
  20. Ellwanger J, Campos D. Abnormality of the Foramen Spinosum due to a Variation in the Trajectory of the Middle Meningeal Artery: A Case Report in Human. *J Neurol Surg Rep*. 2013 May 23;74(02):073–6. doi: <https://doi.org/10.1055/s-0033-1347901>
  21. Ye J, Zheng P, Hassan M, et al. Relationship of the angle between the A1 and A2 segments of the anterior cerebral artery with formation and rupture of anterior communicating artery aneurysm. *J Neurol Sci*. 2017;375:170-174. doi: <https://doi.org/10.1016/j.jns.2017.01.062>
  22. Ji T, Hou K, Li C, Yu J. Imaging features of internal maxillary artery and extracranial middle



meningeal artery and their relationships on head CTA. *Neuroradiol J.* 2021 Dec 27;34(6):629–41. doi: <https://doi.org/10.1177/19714009211019380>